


PRESENTING CLINICAL SIGNS

History: Grade 5/6 right-sided murmur. Asymptomatic.

DATE

2/9/23

ECHOCARDIOGRAPHIC FINDINGS

2D, M-mode, and Doppler study.

PERFORMED BY:

Tasha

Left atrial size is normal. The mitral valve leaflets are mildly thickened, and there is Doppler evidence of mitral regurgitation present. Left ventricular dimensions are normal. Left ventricular systolic function is hyperdynamic. The aorta and aortic valve appear normal. Right atrial and right ventricular dimensions are normal. The tricuspid valve leaflets are mildly thickened, and there is Doppler evidence of tricuspid regurgitation present. The pulmonary artery and pulmonic valve appear normal. No pericardial effusion or cardiac masses are seen.

INTERPRETED BY

 Keith Blass, DVM,
 MS, DACVIM
 (Cardiology)

 LA - 40.9 mm
 LVIDd - 33.8 mm
 LVIDs - 18.4 mm
 FS - 45.5%
 RA - 28.6 mm

PATIENT

Pollyanna Clement

ASSESSMENT/RECOMMENDATIONS

Degenerative mitral and tricuspid valve disease

SPECIES

Canine

This examination demonstrates regurgitation of blood across Pollyanna's mitral and tricuspid valves resulting from degenerative valve disease. The hemodynamic effects of each of the regurgitations also appear to be mild, as Pollyanna does not have secondary dilation of any of her cardiac chambers. As such, Pollyanna's valvular diseases appear to be well-compensated, and her current risk for the development of clinical signs secondary to them, such as coughing, exercise intolerance, syncope, labored breathing, and abdominal distension, appears to be low.

BREED

Australian Cattle Dog

No therapy is recommended at this stage of Pollyanna's valvular diseases.

A recheck echocardiogram is recommended in 6 months to monitor for disease progression.

SEX

FS

AGE

7 y

WEIGHT

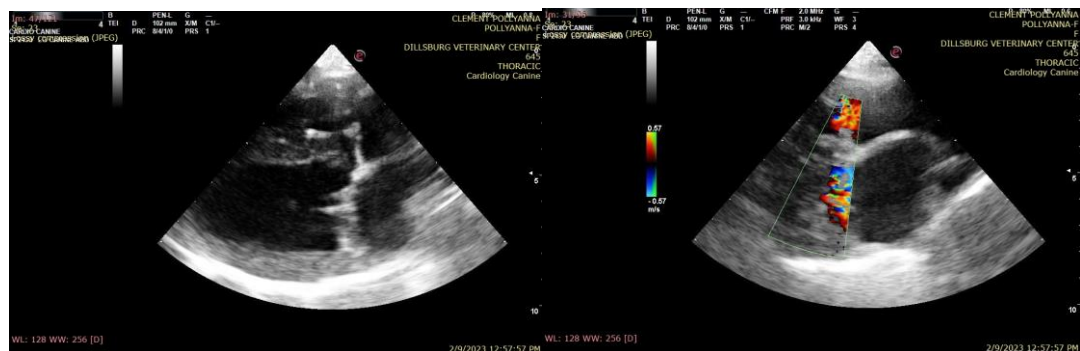
55 lb

HOSPITAL NAME

Dillsburg VC

REFERRING VET

Dr. Jacobs



The information and recommendations provided are based on the images presented by the referring veterinarian. No evaluation can be communicated regarding pathology that was not visible in the image/video clips provided.



Thank you for this referral. If the clinical or image interpretation does not parallel your findings or if I can be of any further assistance please contact me.

DATE

2/9/23

Keith Blass, DVM, MS, DACVIM (Cardiology)
KeithBlass@gmail.com
631-804-5754

PERFORMED BY:

Tasha

INTERPRETED BY

Keith Blass, DVM,
MS, DACVIM
(Cardiology)

PATIENT

Pollyanna Clement

SPECIES

Canine

BREED

Australian Cattle Dog

SEX

FS

AGE

7 y

WEIGHT

55 lb

HOSPITAL NAME

Dillsburg VC

REFERRING VET

Dr. Jacobs